

Long-term outcome after surgical intervention and interventional procedures for the management of Takayasu's arteritis in children

Afksendiyos Kalangos, MD, PhD, DSc, FETCS,^a Jan T. Christenson, MD, PhD, FETCS,^a Mustafa Cikirikcioglu, MD, PhD,^a Dominique Vala, MD,^a Anne Buerge, MD,^b François Simonet, MD,^a Dominique Didier, MD,^c Maurice Beghetti, MD,^b and Edgar Jaeggi, MD^b

Objective: There is little information available on the results of reconstructive arterial surgery for Takayasu's arteritis in children. This study evaluates midterm to long-term outcome after surgical, as well as interventional, procedures.

Methods: From 1984 through 2004, 10 children (5 boys and 5 girls; age, 12.7 ± 2.6 years) with Takayasu's arteritis were referred to our center. Baseline cardiovascular assessment included contrast angiography (n = 4), magnetic resonance imaging-angiography (n = 3), and combined contrast angiography plus magnetic resonance imaging-angiography (n = 3). Two patients had disease confined to the thoracic aorta, 4 had disease confined to the abdominal aorta, and 4 had combined thoraco-abdominal aortic disease. Steno-occlusive lesions were predominant in 92% of cases. Seven patients were maintained on steroid therapy throughout the follow-up period. Eight children underwent complex surgical procedures, 1 patient had balloon dilatation of the renal and mesenteric arteries, and 1 patient had combined vascular surgery with percutaneous transluminal angioplasty. Overall, 24 grafts (polytetrafluoroethylene, Dacron grafts, and cryopreserved homografts) were implanted in various locations.

Results: There were no perioperative deaths. Arterial hypertension regressed in all patients, and cardiac function normalized in all 4 patients with dilative cardiomyopathy. Over a 20-year period, 1 patient presented with sudden death and 2 showed nonfatal disease progression, one of whom required surgical reintervention. The occlusion rate was higher in Dacron grafts.

Conclusions: Our study shows that despite the extent and severity of vascular lesions, children with Takayasu's arteritis could benefit from reconstructive surgery, with low mortality, morbidity, and satisfactory long-term results.

From the Clinic for Cardiovascular Surgery^a and the Department of Radiology,^c University Hospital of Geneva, Geneva, Switzerland, and the Unit of Pediatric Cardiology,^b University Children's Hospital of Geneva, Geneva, Switzerland.

Received for publication Feb 8, 2006; revisions received March 27, 2006; accepted for publication April 18, 2006.

Address for reprints: Afksendiyos Kalangos, MD, PhD, DSc, FECTS, Department of Cardiovascular Surgery, University Hospital of Geneva, 1211 Geneva, Switzerland (E-mail: afksendiyos.kalangos@hcuge.ch).

J Thorac Cardiovasc Surg 2006;132:656-64
0022-5223/\$32.00

Copyright © 2006 by The American Association for Thoracic Surgery

doi:10.1016/j.jtcvs.2006.04.020

Takayasu's arteritis (TA) is a chronic idiopathic inflammatory disease affecting primarily the aorta and its main branches but can also involve the coronary, carotid, pulmonary, and renal arteries.¹ TA constitutes the third most common form of vasculitis in the pediatric population worldwide.²

Steroids or cytotoxic drugs have been shown to improve the systemic inflammatory symptoms associated with the active phase of the disease, although operations and percutaneous transluminal angioplasty (PTA) procedures have been used to treat complications arising from steno-occlusive or aneurysmal lesions in the chronic stage. There are, however, very few reports on surgical and interventional techniques or the evaluation of results over time in the pediatric population.^{3,4}

This article describes our surgical and percutaneous approach in 10 pediatric patients with TA over the past 20 years and evaluates midterm and long-term outcome.

Abbreviations and Acronyms

CA	= contrast angiography
CRP	= C-reactive protein
ESR	= erythrocyte sedimentation rate
LRA	= left renal artery
LVSF	= left ventricular shortening fraction
MRI	= magnetic resonance imaging
PTA	= percutaneous transluminal angioplasty
PTFE	= polytetrafluoroethylene
SMA	= superior mesenteric artery
TA	= Takayasu's arteritis
TTE	= transthoracic echocardiography

Methods**Patients**

From 1984 through 2004, 10 patients were referred to our institution with the diagnosis of TA. There were 5 male and 5 female patients aged 12.7 ± 2.6 years (range, 8-15 years). All patients had been given diagnoses by using the criteria proposed by Sharma and colleagues.¹ Seven patients met the major criteria, and the remaining 3 met the minor criteria. The time interval between the onset of symptoms and diagnosis ranged from 0.5 to 4 years (mean, 2 ± 0.7 years). A common clinical finding was that of arterial hypertension, which was present in 8 patients, with significant renal artery stenosis in 6 of them, 5 being refractory to medication. Increased C-reactive protein (CRP) levels (>5 mg/L) and erythrocyte sedimentation rates (ESRs; ≥ 50 mm/h) were present in 7 patients. Indications for surgical intervention, PTA, or both were high-grade asymptomatic carotid stenosis, limb ischemia or claudication, severe hypertension, mesenteric ischemia, and aortic regurgitation with an associated ascending aortic aneurysm of larger than 5 cm. **Table 1** shows patient demographics and relevant clinical and laboratory findings. This retrospective study was approved by the human studies committee at our institution.

Diagnostic Investigations

All patients underwent extensive cardiovascular assessment either by means of transthoracic echocardiography (TTE), contrast angiography (CA), and/or magnetic resonance imaging (MRI)-angiography preoperatively and after intervention. CA was done in 4 patients, MRI-angiography in 3, and combined CA plus MRI-angiography in the remaining 3. Applying the angiographic criteria reported by Hata and associates,⁵ 2 (20%) of our patients were classified as type II, 2 (20%) as type III, 4 (40%) as type IV, and the remaining 2 as type V (**Figure 1**). Overall, CA, MRI-angiography, or both detected 36 significant vascular lesions: 33 (92%) lesions were stenotic or occlusive, and 3 lesions were dilative or aneurysmal. Stenotic lesions were estimated as mild, moderate, or severe on the basis of the angiographic degree of luminal narrowing of less than 30%, between 30% and 80%, and greater than 80%, respectively.

Four children had TTE findings of dilative cardiomyopathy (patients 2, 5, 6, and 9) with significantly reduced left ventricular shortening fraction (LVSF). In 1 patient (patient 7) severe hypertrophic obstructive cardiomyopathy was responsible for low car-

diac output on admission. Patient 8 had important dilation of the ascending aorta with severe resulting aortic regurgitation. In 9 patients signs of left ventricular hypertrophy were present on a 12-lead electrocardiogram, and 3 patients showed severe cardiomegaly (cardiothoracic index, >0.65) on chest radiography. **Table 2** summarizes all preoperative investigations performed in our series.

Preoperative and Postoperative Corticotherapy

In 7 patients (patients 1, 3-7, and 10) in whom increased preoperative CRP levels of greater than 5 mg/L, an ESR of greater than 50 mm/h, or both was observed, prednisone (0.7 - 1.0 mg/kg⁻¹/d⁻¹) was begun before intervention and then gradually tapered to 0.5 mg/kg⁻¹/d⁻¹ and maintained at 0.25 mg/kg⁻¹/d⁻¹ once clinical remission was obtained throughout the perioperative and follow-up periods to prevent recrudescence of inflammation.

Statistics

Results are expressed as mean values \pm standard deviations. The Wilcoxon signed-rank test was used to compare matched nonparametric values, the Mann-Whitney *U* test was used to compare nonmatched nonparametric values, and the Fisher exact test was used to compare nonmatched parametric values (SPSS, Version 11.5).

Results**Interventions**

Eight children underwent reconstructive surgery. Patient 4 required PTA of the right renal artery and the superior mesenteric artery (SMA), and patient 6 required a combined approach of vascular surgery and PTA. The type of intervention and the graft material used are listed in **Table 3**. Overall, 24 grafts were implanted in various sites: 9 polytetrafluoroethylene (PTFE) grafts, 8 cryopreserved homografts, and 7 Dacron grafts. **Figures 2** and **3** demonstrate examples of preoperative and postoperative angiographic and MRI-angiographic findings in patients 7 and 9. During surgical intervention, a sample of diseased vessel wall was resected for histology. All specimens showed granulomatous panarteritis with identifiable giant cells and lymphoplasmocytic infiltration.

Outcome

Mean hospital stay was 14 ± 2 days, with a range of 10 to 25 days. There were no perioperative deaths, but 1 patient (patient 8) died suddenly of an unknown cause 2 years after an aortic root replacement with a cryopreserved aortic homograft. Unfortunately, postmortem examination was not performed in his country of origin. All patients received a long-term aspirin regimen.

Clinically, all patients were significantly improved after intervention (all patients in New York Heart Association class I or II at 3 months). TTE at 6 months showed improved systolic cardiac function, with an overall increase in LVSF from an average of $25.5\% \pm 13.3\%$ (range, 6%-47%) preoperatively to $32.8\% \pm 6.0\%$ (range, 25%-45%) at 6

TABLE 1. Preoperative patient characteristics

Patient no.	Age (y), sex	NYHA class	Laboratory	Relevant clinical findings
1	15, M	I	CRP ↑, ESR ↑	High BP (210/150 mm Hg)
2	14, F	III-IV	Normal	High BP (160/90 mm Hg), dilative cardiomyopathy
3	12, M	III	CRP ↑, ESR ↑	High BP (190/112 mm Hg), abdominal pain
4	8, M	II	CRP ↑, ESR ↑	High BP (157/87 mm Hg), abdominal pain
5	14, F	I	CRP ↑, ESR ↑	High BP (220/130 mm Hg), dilative cardiomyopathy
6	9, F	III	CRP ↑, ESR ↑	High BP (150/85 mm Hg), dilative cardiomyopathy
7	14, M	III	CRP ↑, ESR ↑	Low BP (70/50 mm Hg), HOCM
8	15, M	III	Normal	Dyspnea on effort (120/40 mm Hg)
9	14, F	III, IV	Normal	High BP (177/127 mm Hg), abdominal pain, dilative cardiomyopathy
10	15, F	II	CRP ↑, ESR ↑	High BP (157/87 mm Hg), abdominal pain

NYHA, New York Heart Association; CRP, C-reactive protein (CRP ↑, >5 mg/L); ESR, erythrocyte sedimentation rate (ESR ↑, >50 mm/h); BP, blood pressure; HOCM, hypertrophic obstructive cardiomyopathy.

months after intervention ($P = .015$). At this time, there was also a significant reduction in left ventricular end-diastolic diameter (from 4.6 ± 0.9 cm to 3.9 ± 0.7 cm, $P = .005$). Importantly, of the 4 patients with dilative cardiomyopathy, the LVSF normalized in 2 (patients 2 and 6: preoperatively from 9% to 14% to 32% and 28%, respectively), and significant improvement was observed in the other 2 patients (patients 5 and 9: preoperatively from 17% and 6% to 27% and 25%, respectively) at 2 years. Patient 7, who had undergone an associated septal myotomy for severe hypertrophic obstructive cardiomyopathy at the time of the initial operation, had residual left ventricular outflow tract obstruction with a peak gradient of 30 mm Hg on the TTE at discharge. However,

with a 1-year β -blocking (propranolol) maintenance therapy, the left ventricular hypertrophy regressed, and the residual outflow tract obstruction disappeared.

After intervention, systemic arterial blood pressure control was more easily and reliably achieved in the 8 patients with abnormal preoperative values, although most required at least one antihypertensive drug (patients 1, 2-4, 6, and 10) or combined (β -blocker plus angiotensin-converting enzyme inhibitor) antihypertensive drug therapy (patients 9 and 5) during the first postoperative year. After this period, the antihypertensive medication maintenance had been completely stopped. All patients, except the first one, remained normotensive throughout the entire follow-up pe-

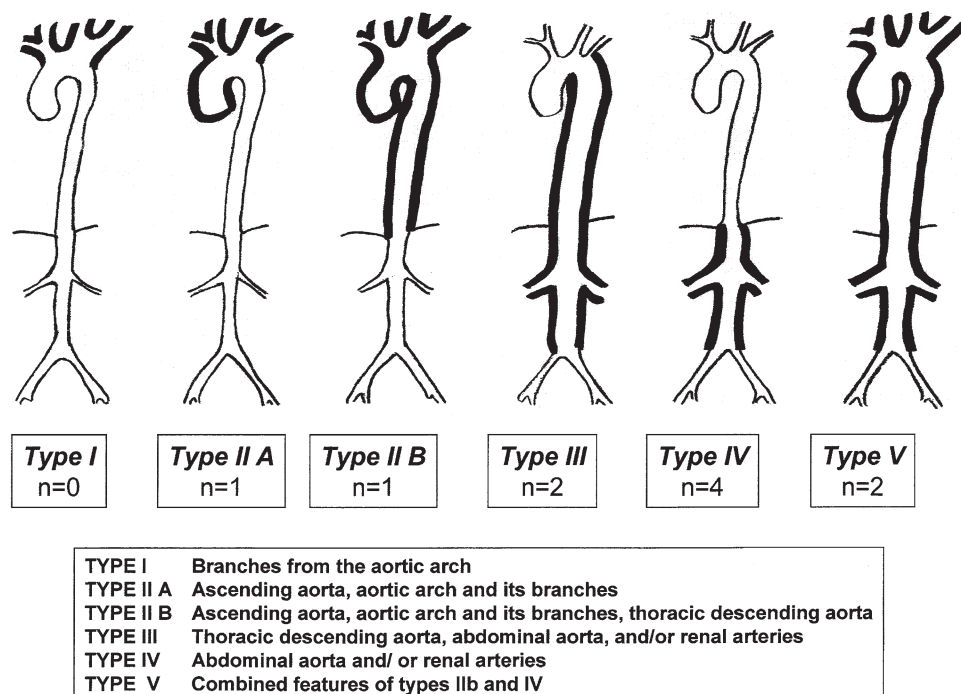


Figure 1. Classification of Takayasu's arteritis and distribution of the cases for each type.

TABLE 2. Preoperative investigations

Patient no.	ECG	CTI	Echocardiography			Diagnosed lesions		
			SF (%)	LVEDD (cm)	Valve functions	Stenosis (n)	Occlusion (n)	Dilatation or aneurysm (n)
1	LVH	0.47	33	4.4		—	CT, SMA, LRA (3)	—
2	LVH	0.69	9	5.8	MR ++ TR ++	TA Ao, SMA, LRA, HA, both IAs (6)	RRA, RFA (2)	TA Ao, CT (2)
3	LVH	0.51	30	4.0	AR +	Abd Ao, both IAs, both RAs (4)	—	—
4	Normal	0.46	38	4.2		SMA, RRA (2)	—	—
5	LVH	0.70	17	6.0	MR ++ AR ++	Abd Ao, both RAs (3)	—	—
6	LVH	0.72	14	6.1		Desc Ao, RRA (2)	—	—
7	LVH	0.50	47	3.2		Asc Ao, aortic arch and supra-aortic vessels (5)	—	—
8	LVH	0.59	32	4.4	AR ++++ MR +	—	—	Asc Ao (1)
9	LVH	0.53	6	4.2	MR ++ TR ++ AR +	Desc Ao, RRA (2)	Abd Ao, LRA (2)	—
10	LVH	0.45	29	4.0		TA Ao, LCA (2)	—	—

ECG, Electrocardiography; CTI, cardiothoracic index; SF, shortening fraction; LVEDD, left ventricular end-diastolic diameter; LVH, left ventricular hypertrophy; CT, celiac trunk; SMA, superior mesenteric artery; LRA, left renal artery; MR, mitral regurgitation; TR, tricuspid regurgitation; TA Ao, thoracic and abdominal aorta; HA, hepatic artery; IA, iliac artery; RRA, right renal artery; RFA, right femoral artery; AR, aortic regurgitation; Abd Ao, abdominal aorta; RA, renal artery; Desc Ao, descending aorta; Asc Ao, ascending aorta; LCA, left carotid artery.

riod. Therapy-resistant systemic hypertension redeveloped in patient 1 because of progressive right renal artery stenosis, which had only been mild in 1989. When the patient returned to our center in 2001 at the age of 27 years, this renal artery had become completely occluded, and the atrophic kidney had to be removed.

All patients had follow-up assessments between 1 and 20 years (mean, 12.3 ± 5 years) after intervention. This included diagnostic repeat studies of cardiovascular lesions by means of CA and MRI-angiography (6 CAs, 8 MRI-angiographies, and 2 MRIs, with subsequent CAs between 1 and 10 years postoperatively; 1 CA, 3 MRI-angiographies, and 1 MRI, with subsequent CAs between 10 and 20 years postoperatively; Figures 2-4). Table 3 summarizes the midterm and long-term postoperative outcome based on data from CA and MRI-angiography. Two patients required redo operations between the first and fifth postoperative years for progressive occlusion of the abdominal aorta, stenosis of both renal arteries, and occlusion of the SMA Dacron graft at the proximal anastomosis in patient 1. This patient was resistant to steroid therapy, and cytotoxic drug therapy could not be instigated because of difficulties in the management of these drugs in his country of origin. Patient 5 had stenosis of the left renal artery (LRA) and aneurysmal dilatation of the abdominal aortic homograft. Patient 6 underwent redo PTA of the right renal artery after 5 years. Between the first and fifth postoperative years, 2 of the 7

Dacron grafts developed significant stenosis (patient 1), and 2 of the 8 homografts developed lesions, with 1 aneurysmal and 1 stenotic lesion (patient 9). Histopathologic examination of the deteriorated homograft showed extensive transparietal fibrosis with increased neovessel formation and several fibrolipidic plaques, with no evidence of calcification or acute inflammation.

One patient had significant stenosis at the distal anastomosis of the SMA Dacron graft (patient 2) between the sixth and tenth postoperative years and subsequently underwent successful PTA.

One patient had reocclusion of the SMA Dacron graft and the right renal Dacron graft (patient 1) between the 11th and 20th postoperative years. The SMA had well-developed collateral circulation, but the right kidney was atrophic and required right nephrectomy.

The overall restenosis or graft occlusion rate was 18% (4/24 grafts) between the first and fifth postoperative years, decreasing to 5% (1/20 grafts) between the 6th and 10th postoperative years and to 10% (2/19 grafts) between the 11th and 20th postoperative years. The stenosis or aneurysmal formation rate with cryopreserved homografts was 25% (2/8 grafts) over a period of 11 years (between 1993 and 2004), whereas a stenosis and occlusion rate of 70% (5/7 grafts) was observed in Dacron grafts over a period of 20 years. None of the 9 PTFE grafts presented significant

TABLE 3. Interventions and postoperative outcome

Patient no.	Date	Intervention	Postoperative treatment	Postoperative outcome		
				1-5 y	6-10 y	11-20 y
1	1984	Ao-LRA (8 mm), SMA (6 mm), HA (6 mm) bypasses with Dacron grafts	Prednisolone Aspirin	Replacement of Abd Ao with reimplantation of the previous SMA graft and both RAs bypasses with Dacron grafts after 3 y	Mild stenosis of the distal anastomosis of RRA bypass	Occlusion of the RRA and SMA bypasses; right nephrectomy after 17 years
2	1986	Asc Ao–bilateral iliac arteries bypass with Dacron graft (10-8 mm) + reimplantation of SMA + graft–both RAs (6 mm) bypasses with PTFE grafts	Aspirin	Mild stenosis of the distal anastomosis of SMA artery after 5 y	PTA of the distal anastomosis of SMA + mild stenosis of the distal anastomosis of both RAs after 10 y	Moderate stenosis of the distal anastomosis of both RAs
3	1989	Asc Ao–bilateral iliac arteries bypass with Dacron graft (10-8 mm) + Ao-LRA (8 mm) + Ao-SMA (6 mm) bypasses with PTFE grafts	Prednisolone Aspirin	No stenosis	Mild stenosis of the distal anastomosis of the iliac arteries, LRA and SMA after 8 y	Moderate stenosis of the distal anastomosis of LRA and SMA
4	1992	PTA of SMA and RRA	Prednisolone Aspirin	No stenosis	Mild stenosis of RRA and SMA after 7 y	Mild stenosis of RRA and SMA after 12 y
5	1993	Replacement of Abd Ao with PTFE graft (14 mm) + graft–both RAs bypasses (6 mm) with homograft	Prednisolone Aspirin	Mild stenosis of the distal anastomosis of LRA at 5 y	Mild stenosis of the distal anastomosis of both RAs after 10 y	Moderate stenosis of the distal anastomosis of both RAs
6	1995	Ao isthmus–Abd Ao bypass with PTFE graft (14 mm) + PTA of RRA	Prednisolone Aspirin	Re-PTA of RRA after 5 y	Mild stenosis of the distal anastomosis of RRA after 9 y	
7	1997	Replacement of Asc Ao and aortic arch with 2 homografts (19 mm; septal myotomy)	Prednisolone Aspirin	Normal		
8	1998	Aortic root replacement with homograft	Aspirin	Died 2 y after operation (unknown cause)		
9	1999	Replacement of Abd Ao with homograft (16 mm) + graft–both RAs bypasses with homografts (6 mm)	Aspirin	Rereplacement of the Abd Ao (Dacron) and re-bypass (PTFE) to LRA after 5 y		
10	2003	Asc Ao–bilateral iliac arteries bypass with PTFE graft (10-8 mm) + Asc Ao–LCA bypass with PTFE graft (7 mm)	Prednisolone Aspirin	Mild stenosis of the distal anastomosis of LCA and right iliac artery after 1 y		

Ao, Aorta; LRA, left renal artery; SMA, superior mesenteric artery; HA, hepatic artery; Abd Ao, abdominal aorta; RA, renal artery; RRA, right renal artery; Asc Ao, ascending aorta; PTFE, polytetrafluoroethylene; PTA, percutaneous transluminal angioplasty; LCA, left carotid artery.

stenosis or occlusion over the 20-year period. The mean follow-up period for Dacron grafts was 18 ± 2.2 years and was statistically longer than for the PTFE grafts (9.9 ± 7.3 years, $P = .01$) and homografts (7.1 ± 2.5 years, $P = .001$). The freedom from occlusion/restenosis was statistically sig-

nificant in favor of the PTFE grafts (100%) compared with the Dacron grafts (58%) at 7 years ($P = .005$). However, the freedom from occlusion/restenosis between PTFE grafts and homografts (75%) at 7 years was not statistically significant (Figure 5).

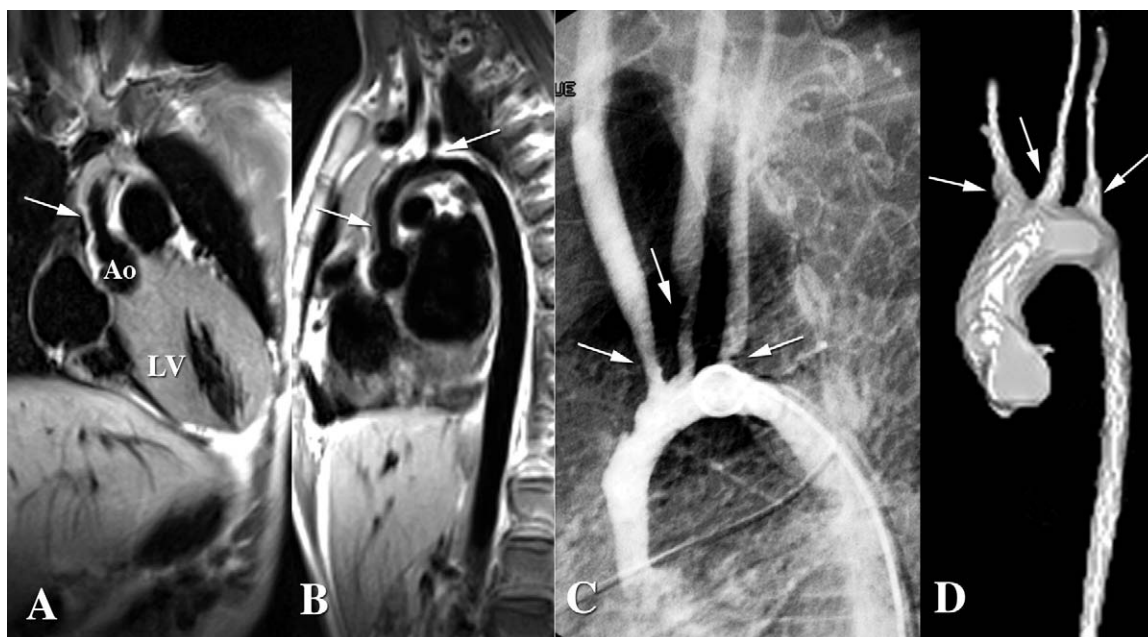


Figure 2. Preoperative magnetic resonance imaging (patient 7) showing severe obstructive hypertrophic cardiomyopathy of the left ventricle (A) and thickening of the aortic wall (B). C, Preoperative angiography showing narrowing of the ascending aorta and the aortic arch and stenosis of all cervical branches. D, Postoperative magnetic resonance imaging 2 years after homograft replacement of the ascending aorta, aortic arch, and proximal segments of the supraortic trunks, with no evidence of homograft calcifications or degeneration.

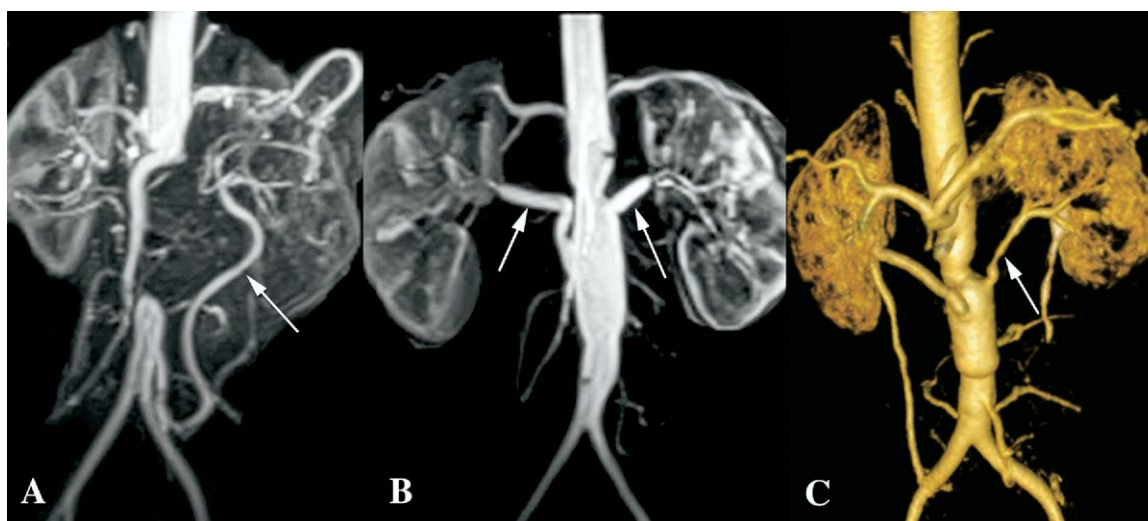


Figure 3. A, Preoperative magnetic resonance imaging-angiography (patient 9) showing complete occlusion of a long segment of the infrarenal aorta and perfusion of the distal aorta through Riolan's arcade and the inferior mesenteric artery. B, Postoperative magnetic resonance imaging-angiography at 6 months showing patency of the abdominal aortic homograft and the 2 renal artery homografts without signs of restenosis or graft degeneration. C, Postoperative magnetic resonance imaging-angiography at 5 years showing aneurysmal dilatation of the abdominal aortic homograft with diffuse stenosis of the left renal homograft artery.

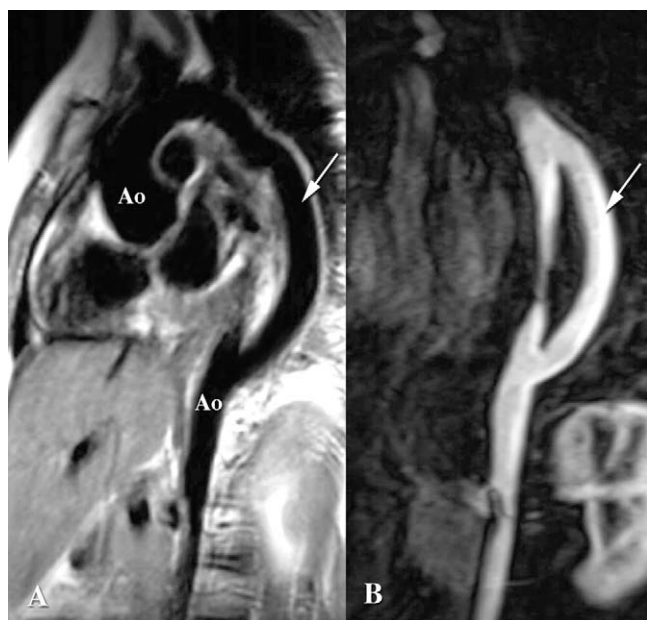


Figure 4. Magnetic resonance imaging (A) and magnetic resonance imaging-angiography (B; patient 6) showing a patent polytetrafluoroethylene bypass graft from the thoracic to abdominal aorta (Ao) at 2 postoperative years.

During follow-up, both patients (patients 4 and 6) who initially underwent PTA interventions experienced restenosis, one being a severe case estimated at 90% that was successfully dilated (case 6) 3 years after initial PTA and the other being a mild case (30%) not requiring any intervention as of yet.

Discussion

TA is a rare disease in most western countries. In the early stages of the disease, prominent symptoms can be nonspecific, and vasculitis frequently remains unrecognized. Thus diagnosis is usually delayed once ischemic events become manifest in the late steno-occlusive phase.^{6,7} The delay in diagnosis was 2 years in our pediatric population, which is like that reported by Hoffman,⁸ who also showed that this delay was shorter (5 months) in adults.

CA has been the gold standard diagnostic approach for evaluation of vascular lesions in the past. At our institution, MRI-angiography has progressively replaced CA over time in the diagnosis and evaluation of the arterial system in patients with TA, especially because it avoids the use of radiation and important quantity of nephrotoxic contrast dyes in the pediatric population. MRI techniques allow for the measurement of both arterial wall thickness and edema, findings that correlate with clinical symptoms of acute vasculitis.⁹ However, MRI-angiography has some limitations in detecting lesions in the digestive and renal arteries and in

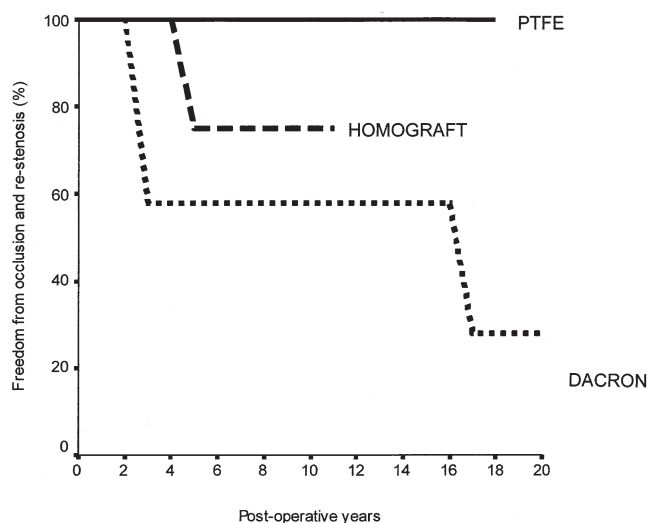


Figure 5. Freedom from occlusion/restenosis over the follow-up period. PTFE, Polytetrafluoroethylene.

the supra-aortic trunks,¹⁰ so that 3 of our patients required additional CA for adequate topographic information on the extension and severity of the arterial lesions. Computed tomography has not been used as a diagnostic tool at our institution, even though there are recent reports showing excellent results with this technique, which might someday rival CA as the standard method of diagnosis.¹¹

In our series 92% of the observed lesions consisted of vascular stenoses of varying degrees of severity. Dilative lesions have been reported to occur in 2% to 27% of cases of TA,¹² and our series had an 8% incidence. Mild aortic insufficiency is not uncommon, with a reported incidence of 7% to 16%,^{13,14} being 30% in our series. Moreover, an aneurysmal ascending aorta with severe aortic insufficiency was the predominant indication for surgical intervention in patient 8.

Nine of our 10 patients preferentially underwent vascular reconstructive surgery for lesions too extensive to be approached by means of interventional catheter procedures alone and too advanced and severe to be treated pharmacologically. Thanks to improvements in anesthesia, surgical techniques, and postoperative care, even high-risk patients, such as those with low LVSF or dilative cardiomyopathy, which constituted 40% in our series, can now be approached surgically, with excellent immediate, midterm, and long-term results and low morbidity and improved quality of life, as confirmed by our data.

A wide variety of graft materials was used in our patients, with the choice of Dacron or PTFE being surgeon related up until 1993. Since 1993, the preferred graft material for children became the cryopreserved arterial homografts when available. Eight (62%) of the 13 grafts used

between 1993 and 2004 were indeed homografts in an effort to improve the long-term graft patency of the small arteries and to avoid long-term anticoagulation therapy in aortic valve replacement, which is particularly important in developing countries, in which periodic international normalized ratio controls are uncertain. Two homografts degenerated in a child not started on steroids postoperatively, thus requiring a redo operation. However, there was no observed structural deterioration of homograft in the remaining patients, all of whom did receive postoperative steroid treatment, as evidenced by repeat MRI-angiographies over an 11-year period. This might be explained by the immunosuppressive effect of steroids attenuating the immune reaction against homografts,¹⁵ which has been speculated to contribute to early homograft deterioration in children. Although graft material of choice remains unclear because of the limited number of cases, our results with Dacron grafts (70% occlusion rate in this series) correspond to those reported earlier by Kerr,¹⁶ who also found Dacron grafts to be less favorable conduits in these patients. In our series all significant restenoses occurred at the distal anastomotic sites between the Dacron grafts and native arteries, except in patient 9, in whom restenosis of the homograft conduit to the LRA was diffuse, affecting the entire length of the homograft. The main reason for restenoses at the distal anastomoses is that the bypass of the affected vessels originated from either an implanted graft or uninvolved area of the aorta to a point with macroscopically unsuspected active disease, which is often difficult to precisely assess during surgical intervention, in addition to the inability to predict future involvement of an otherwise normal-appearing segment.

Endovascular therapy is theoretically attractive for the treatment of relatively short lesions amenable to PTA, stenting, or both, with multiple case reports and series describing applications to the great vessels, aorta, and renal arteries.¹⁷⁻²⁴ Despite a high initial success rate, restenosis of vessels having undergone angioplasty or stented vessels occurred between 25% and 60% of cases within 2 years.¹⁷⁻²⁴ Moreover, data describing long-term patency and outcomes are lacking. This high rate of restenosis might be due to application of endovascular procedures at sites of unsuspected active disease.

Congestive heart failure in children with TA might be caused by long-standing systemic arterial hypertension and exceptionally to severe aortic insufficiency. In our series 4 children presented with severe dilative cardiomyopathy with an LVSF of 17% or less, most likely caused by increased afterload from severe reno-occlusive arterial hypertension, as well as to extended thoracoabdominal or abdominal aortic stenosis. After relief of renal obstruction either by means of surgical intervention (patients 2 and 5) or catheter balloon dilatation (patient 6), systolic function normalized completely in 2 patients, whereas it improved to

nearly normal systolic function within the 6 first months postoperatively in the other 2 patients.

On the basis of previously published data, it is not clear why the 5-year mortality in children is higher than in adults (35% vs 3% to 7%, respectively).^{25,26} It has been speculated that systemic inflammation progresses, particularly in the pediatric population, and that this might influence long-term survival.²⁷ In 7 of our patients admitted with high preoperative CRP and ESR values, prednisone was administered before and maintained after surgical intervention to prevent disease progression. Only one of these 7 patients was resistant to prednisone and later had restenosis and subsequent occlusion of his grafts over the follow-up period of 20 years. On the other hand, of the remaining 3 patients with normal preoperative CRP and ESR values who were therefore not started on prednisone, the first had restenoses of the bypassed vessels requiring PTA, the second died of an unknown cause 2 years after surgical intervention, and the third experienced homograft deterioration requiring a redo operation at 5 years after surgical intervention. Nevertheless, when compared with previous reports on survival rates in children with TA, our series demonstrates better mid-term and long-term prognosis, even for particularly severely affected children. We believe that this could be related to permanent remission induced by nonstop steroid therapy. Moreover, lesions associated with TA can sometimes heal with steroids alone. In our series the majority of patients with a mild degree of stenoses remained stable with corticotherapy.

Conclusion

Our study shows that despite the extent and severity of vascular lesions, all children with TA could be amenable to reconstructive procedures with low mortality and morbidity risks and satisfactory midterm and long-term results. Permanent postoperative steroid therapy seems to play an important role in the improvement of survival by preventing the persistence of inflammation and progression of vascular lesions over time. Systolic cardiac function, which can be severely impaired in some cases before intervention, might fully recover within weeks to months after intervention. In our experience with steroid therapy, the restenosis rate appears to be lower for PTFE grafts and cryopreserved homografts than for Dacron grafts. However, because the disease can progress despite anti-inflammatory therapy, all patients with TA undergoing operations require regular follow-up assessment (preferably with MRI-angiography) of the aortic segments and interposed grafts to prevent the consequences of gradually impaired organ dysfunction.

References

1. Sharma BK, Jain S, Suri S, Numano F. Diagnostic criteria for Takayasu's arteritis. *Int J Cardiol.* 1996;54(suppl):S127-33.

2. Brogan PA, Dillon MJ. Vasculitis from the pediatric perspective. *Curr Rheum Rep.* 2000;2:411-6.
3. Robbs JV, Abdool-Carrim ATO, Kadwa AM. Arterial reconstruction for non-specific arteritis (Takayasu's disease): medium to long-term results. *Eur J Vasc Surg.* 1994;8:401-10.
4. Ivarsson SA, Bergqvist D, Lundstrom NR, Maly E, Nilsson KO, Wattsgard C. Takayasu's aortitis with renovascular hypertension. *Acta Paediatr.* 1992;81:1044-8.
5. Hata A, Noda M, Moriwaki R, Numano F. Angiographic findings of Takayasu arteritis: new classification. *Int J Cardiol.* 1996;54(suppl):S155-63.
6. Ishikawa K. Effects of prednisolone therapy on arterial angiographic features in Takayasu's disease. *Am J Cardiol.* 1991;68:410-3.
7. Lupi HE, Seoane M. Takayasu's arteritis (nonspecific aortoarteritis) In: Land A, Berkman YM, McAllister HA Jr, editors. Aortitis: clinical, pathologic, and radiographic aspects. New York: Raven Press; 1986. p. 173-91.
8. Hoffman GS. Takayasu arteritis: lessons from the American National Institutes of Health experience. *Int J Cardiol.* 1998;66(suppl):S191-4.
9. Tso E, Flamm SD, White RD, et al. Takayasu arteritis: utility and limitations of magnetic resonance imaging in diagnosis and treatment. *Arthritis Rheum.* 2002;46:1634-42.
10. Yamada I, Numano F, Suzuki S. Takayasu arteritis: evaluation with MR imaging. *Radiology.* 1993;188:89-94.
11. Park JH. Conventional and CT angiographic diagnosis of Takayasu arteritis. *Int J Cardiol.* 1996;54(suppl):S135-41.
12. Kumar S, Subramanian R, Ravi Mandalam K, et al. Aneurysmal form of aortoarteritis (Takayasu's disease): analysis of thirty cases. *Clin Radiol.* 1990;42:342-7.
13. Touré MK, Pasquier G, Herremans F, Bonnin A, Fouchard J, Houille F. Anévrismes au cours de la maladie de Takayasu. *Arch Mal Coeur.* 1982;75:695-700.
14. Kalangos A, Baldovinos A, Beghetti M, Vala D, Faidutti B. Ascending aortic aneurysm associated with aortic insufficiency due to Takayasu's arteritis. *Ann Thorac Surg.* 1999;68:248-50.
15. Shaddy RE, Hawkins JA. Immunology and failure of valved allografts in children. *Ann Thorac Surg.* 2002;74:1271-5.
16. Kerr GS. Takayasu's arteritis. *Curr Opin Rheumatol.* 1994;6:32-8.
17. Tyagi S, Khan AA, Kaul UA, Arora R. Percutaneous transluminal angioplasty for stenosis of the aorta due to aortic arteritis in children. *Pediatr Cardiol.* 1999;20:404-10.
18. Saxena A, Kothari SS, Sharma J, Juneja R, Srivastava S. Percutaneous transluminal angioplasty of the aorta in children with nonspecific aortoarteritis: acute and follow-up results with special emphasis on left ventricular function. *Catheter Cardiovasc Interv.* 2000;49:419-24.
19. Deyu Z, Lisheng L, Ruping D, Haying W, Guozhang L. Percutaneous transluminal renal angioplasty in aortoarteritis. *Int J Cardiol.* 1998; 66(suppl):S205-11.
20. Rao SA, Mandalam KR, Rao VR, et al. Takayasu arteritis: initial and long-term follow up in 16 patients after percutaneous transluminal angioplasty of the descending thoracic and abdominal aorta. *Radiology.* 1993;189:173-9.
21. Sharma BK, Jain S, Bali HK, et al. A follow-up of balloon angioplasty and de-novo stenting in Takayasu arteritis. *Int J Cardiol.* 2000; 75(suppl):147-52.
22. Takahashi JC, Sakai N, Manaka H, et al. Multiple supra-aortic stenting for Takayasu arteritis: extensive revascularization and two-year follow-up. *Am J Neuroradiol.* 2002;23:790-3.
23. Park JH, Han MC, Kim SH, et al. Takayasu arteritis: angiographic findings and results of angioplasty. *Am J Roentgenol.* 1989;153:1069-74.
24. Bali HK, Jain S, Jain A, et al. Stent supported angioplasty in Takayasu arteritis. *Int J Cardiol.* 1998;66(suppl):S213-7.
25. Morales E, Pineda C, Martinez-Lavin M. Takayasu's arteritis in children. *J Rheumatol.* 1991;18:1081-4.
26. Ishikawa K, Maetani S. Long-term outcome for 120 Japanese patients with Takayasu's disease. *Circulation.* 1989;80:429-37.
27. Dabague J, Reyes PA. Takayasu arteritis in Mexico: a 38-year clinical perspective through literature review. *Int J Cardiol.* 1996;54(suppl): S103-9.